

Research Journal of Pharmaceutical, Biological and Chemical Sciences

Natural Tooth Pontic – Natural Way of Preservation.

Senthil Rajan RS¹, Senthil Kumar T², Krishna Kripal^{1*}, and Nehal N Sanghani¹.

¹Department of Periodontology, Rajarajeswari Dental College and Hospital, Bangalore, Karnataka, India,

²Department of Conservative Dentistry and Endodontics, College of Dental Sciences and Hospital, Indore, Madhya Pradesh, India,

ABSTRACT

There is probably nothing more disheartening for patients to learn that a tooth is hopeless and should be extracted. Sudden loss of an anterior tooth is a catastrophic event for any patient. The primary causes for tooth loss can be due to trauma, periodontal disease, or endodontic failure. As clinicians, we are highly empathetic and concerned for the patient's aesthetic and optimal functional requirements. The road to restoration can be filled with a series of complex procedures, often entailing a multidisciplinary approach. A 42-year-old male patient reported with a complaint of a mobile mandibular right central incisor after an episode of trauma one week back. Clinical examination revealed. Grade III mobility in relation to 41. Radiographic examination revealed extensive periradicular bone loss in relation to 41 and was indicated for extraction. Due to the high aesthetic demands of the patient, natural tooth pontic as a provisional restoration was planned for the patient. Utilizing the patient's natural clinical crown as a fixed interim pontic is often a superior alternative to fixed partial prosthesis. The abutment teeth can be preserved with minimal or no preparation, thus keeping the technique reversible, and also can be completed at the chair side thereby avoiding laboratory costs.

Keywords: Aesthetics; natural tooth pontic; periodontally compromised.

**Corresponding author*



INTRODUCTION

It is very disheartening for patients to learn that a tooth is hopeless and must be extracted. The loss of tooth is a heart breaking experience for any patient. The principle reasons for tooth loss can be due to trauma, periodontal disease, endodontic failure etc. Whenever missing tooth structure is to be replaced, the clinician should consider numerous factors, including natural tooth preservation, minimal intervention, aesthetics, and cost. Certain situations demand the clinician to remove an anterior tooth. These conditions may include dental trauma, advanced periodontal disease, extensive root resorption, and endodontic failure.

For a patient who requires removal of an anterior tooth, the primary concern is restoration of aesthetic appearance immediately to avoid aesthetic, masticatory, and phonetic difficulties and also to prevent the drift of adjacent teeth [1]. Whether the tooth is removed surgically or lost due to trauma the clinician should also consider an immediate means to satisfy the patient's cosmetic requirements.

Removable temporary partial dentures made from denture base resin in the immediate post extraction phase are unaesthetic due to presence of clasp, [2] which impede the healing process and jeopardize the periodontal health of the remaining dentition [3].

Using the natural tooth as pontic offers the benefits of using the right size, shape and color [4]. Natural tooth pontic (NTP) suitably modified and bonded to adjacent teeth enables proper healing in the area without compromising the anterior aesthetic demands of the patient. NTP offers excellent color, shape, and size match and thus enhances the psychological and social acceptability of the patient with a minimal cost involved [5].

In the past there have been a number of different techniques described in the restorative dentistry literature for splinting teeth and adding a natural tooth pontic, denture tooth, or composite resin tooth pontic. A variety of periodontal splint materials such as the multi-flex orthodontic wires, steel or nylon meshes, glass, wire or fibre splint etc. can be used to splint the pontic to the adjacent stable abutments via composite resin [6]. These pontics were connected to the adjacent teeth with adhesive composite resins, wire, metal mesh, nylon, mesh and cast metal frameworks bonded to the adjacent teeth.

This case report presents the use of unsalvageable natural tooth as pontic and splinting them using a fibre splint and flowable composite.

CASE REPORT

A 42-year-old male patient reported to the Department of Periodontology, Rajarajeswari Dental College and Hospital, Bangalore with a complaint of a mobile mandibular right central incisor. While recording case history, patient did not reveal any significant medical history. Dental history revealed an episode of trauma in the mandibular anterior region one

week back. On clinical examination, the mandibular right central incisor showed Grade III mobility, whereas right lateral incisor showed Grade I mobility and the adjacent (left) central and lateral incisor Grade II mobility. Radiographic examination revealed extensive periradicular bone loss in relation to 31. Both clinical and radiographic examinations indicated extraction of the mandibular right central incisor due to poor periodontal prognosis. Because of the high aesthetic demands of the patient, immediate bonding of the natural tooth pontic as a provisional restoration was performed. The patient was duly informed about possible limitations and outcome of the procedure.

Technique

Initial Treatment

After formulating treatment plan, alginate impressions of upper and lower arch were taken and casts were prepared. The tooth was atraumatically extracted under local anaesthesia and hemostasis was achieved. The extracted tooth crown was separated from fracture root using diamond disc and stored in saline until chair side procedure.

Customising the Extracted Natural Tooth

The extracted tooth was scaled/cleaned off all its attachments with ultrasonic scaler. After sectioning the newly created apical opening of the coronal portion of the pulp canal is cleaned with 3% sodium hypochlorite, enlarged slightly and sealed with micro-filled hybrid composite (FILTEC Z 250,3M ESPE,USA). A modified ridge lap shape is given to cervical area to facilitate cleaning and appearance of emerging profile. Position of this natural tooth pontic was tried on the cast.

Teeth Preparation for Bonding

Following satisfactory try-in and occlusal adjustments, the abutment teeth were roughened using coarse flame shaped diamond abrasive instrument then isolated, cleaned and dried. The pontic was also cleaned with pumice, washed and dried. The abutment teeth and pontic were then etched with 37% ortho-phosphoric acid (Ultradent, USA) for 30 s, washed and dried. Dentin bonding agent (Prime and Bond, Dentsply, USA) was applied to the etched enamel and light cured. A thin layer of composite resin (Flowable Composite 3M ESPE) was placed across the abutment teeth and pontic. The well contoured pontic was then placed in its original position and its final position was determined with reference to the adjacent teeth. The pre-cut fibre strip was thoroughly wetted using the unfilled resin, placed over the composite and cured. A further layer of composite was placed over the tape, ensuring that all of it was covered by composite, and cured. Excess composite resin was removed and occlusal interferences were again checked in protrusion and lateral excursions. Finishing and polishing procedures were carried out using composite finishing discs.

The patient was instructed to primarily keep the site free of plaque and debris. Use of interdental brushes was demonstrated to the patient to enable good oral hygiene. First recall appointment was made 1 week later. The patient was highly motivated by the aesthetic result as well as improved ease of biting with no discomfort. The patient was followed-up for a period of 1 month, at the end of which various treatment options available were explained to him.

DISCUSSION

The restoration of a smile is one of the most appreciating and gratifying services a dentist can render. Immediate replacement of lost anterior teeth prevents psychological and social trauma to the patient. Removable appliances or prostheses seem to be one suitable treatment option, but patient compliance is generally a major problem, besides compromised aesthetics because of canine clasps that are commonly used to provide stability and to enhance retention. Moreover, partial removable dentures are frequently subjected to fracture.

This case report describes a simple, economical and quick method to improve the esthetics of patients having periodontally compromised with hopeless prognosis. Single-tooth replacement options include conventional fixed partial dentures, a removable partial denture and a single-tooth implant. Dental implants in the esthetic zone are well documented in the literature but such restorations are sometimes complicated by the cost of the restoration, patient's fear of the surgical procedure, and anatomical limitations.

The development of adhesive systems has provided other treatment options with minimally invasive preparations and is often simpler [7,8]. Replacement of a single tooth with natural tooth pontic was preferred in the current case to immediately restore the esthetics of patient because this chair side technique does not require laboratory procedures. The use of the extracted tooth, aided by the impressive bond strength of dental adhesive materials, provides an option to treat patients with less invasive tooth preparation, favorable esthetics, and a natural feeling.

Natural pontic which was used in this case provided psychological benefits and a perfect esthetic match. Besides the use of resin composite to splint the pontic to neighbouring sound teeth, the possibility of utilizing orthodontic wire or fibre splint has become possible. One major advantage of retaining the patient's natural crown is that, the patient can better tolerate the effect of tooth loss. Moreover, it provides the optimal pontic in terms of shape, colour, size and alignment [5].

The key advantages of this technique are excellent aesthetic results; preservation of natural crown structure; extracted tooth replaced at the same visit; no laboratory work required; reduces psychological impact on the patient; technique is reversible and allows other restorative options to be evaluated; can be used as an interim or definitive prosthesis; micro-resiliency of pontic allows stimulation of underlying tissue and avoids excessive post-extraction ridge resorption. The pontic was given a modified ridge shape to achieve a mild contact with alveolar ridge, for better preservation of the soft tissue health [8] and for a better emergence

profile. Two studies have shown a successful long term follow-ups of such natural tooth pontics [9,10].

The procedure is associated with a number of limitations like relying on patient's motivation and maintenance of oral hygiene, limited functional efficiency, irritation to the tongue and chances of splint breakage. Presence of mal-aligned or pathologically migrated teeth especially if more than one, sometimes poses a problem in placement of these pontics due to limited space to accommodate them. The major limitation anticipated in this treatment was of functional efficacy; hence, a more permanent solution must be offered to the patient.

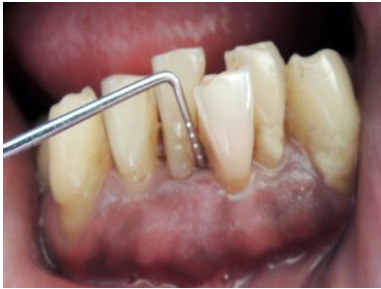

Figure 1: Preoperative view

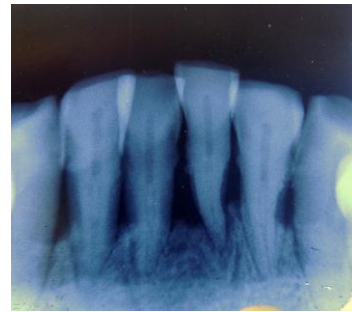


Figure 2: IOPAR showing lower anteriors

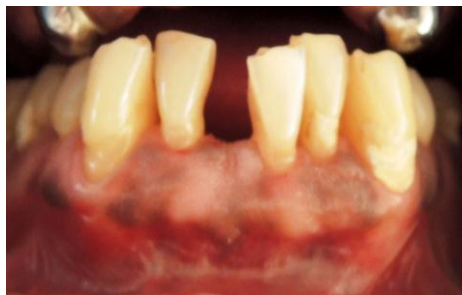

Figure 3: Post extraction view

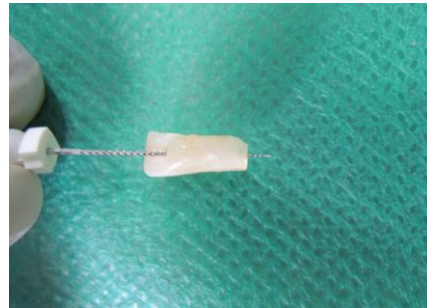


Figure 4: 41 after root resection and pulp extirpation

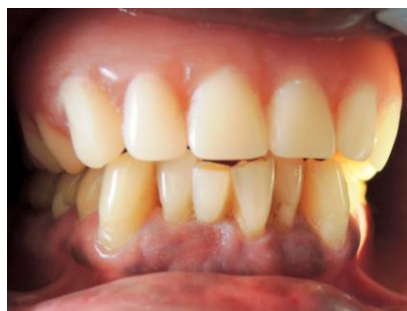

Figure 5: Postoperative view after splinting of natural pontic and in occlusion.



CONCLUSION

Natural teeth can serve as an excellent yet transient treatment option for immediate replacement in the anterior esthetic zone. The patient satisfaction of continuing to have their natural teeth in the post-extraction period, taking care of his esthetic needs and simultaneously providing him with time to choose from the various final treatment options available is immense. Patient's positive psychological response, cost- effectiveness, and achievement of excellent soft tissue contours make this technique very useful and acceptable.

REFERENCES

- [1] Freilich MA, Meiers JC, Duncan JP, Goldberg AJ. Quintessence 2000; 49–70.
- [2] Ulusoy AT, Cehreli ZC. Dent Traumatol 2008; 24: 96-9.
- [3] Bissada NF, Ibrahim SI, Borsoum WM. J Periodontol 1974; 45: 651-9.
- [4] James L, Kretzschma R. J Am Dent Assoc 2002; 132: 1552-1553.
- [5] Parolia A, Shenoy KM, Thomas MS and Mohan M. Aust Endod J 2010; 36: 35–38.
- [6] Stumpel LJ. J Calif Dent Assoc 2004; 32: 257- 60.
- [7] Iglesia-Puig MA, Arellano-Cabornero A. J Prosthet Dent 2003; 89: 443–5.
- [8] Edelhoff D, Spiekerman H, Yildirim M. Quintessence Int 2001; 32: 269–81.
- [9] Stein RS. J Prosthet Dent 1996; 16: 251-85.
- [10] Kermanshah h, Motevasselian F. Oper Dent 2010; 35: 238-45.